

A New Technique Involving a Spherical Stainless Steel Device to Optimize Positioning of the Umbilicus

Arian Mowlavi · Peter M. Huynh · Douglas C. Huynh ·
Bradon J. Wilhelmi



Received: 1 February 2012 / Accepted: 15 April 2012 / Published online: 7 July 2012
© Springer Science+Business Media, LLC and International Society of Aesthetic Plastic Surgery 2012

Abstract

Background Creating an aesthetically pleasing umbilicus may be challenging due to various factors that involve the patient limitations and suboptimal techniques available to the surgeon. Although many techniques aim to locate the umbilicus after abdominoplasty, none are ideal. The authors use a new technique involving a stainless steel spherical device for definite location of the new neo-umbilicus site.

Methods Abdominoplasty with full muscle plication and umbilicoplasty was performed to test the effectiveness of this new technique that involves a stainless steel marble called the Umblicator. It has a diameter of 1.5 cm and three 2-mm holes drilled 120° apart in an equilateral triangle. The Umblicator is secured to the inferior and superior dermis of the umbilical stalk to help identify the future location of the umbilicus on the abdominal skin. Once the marble is secured, the superior abdominal flap is redraped and trimmed, the suture is repaired, and the location of the umbilicus is determined by feeling for the

smooth spherical surface bump with gentle downward pressure on the overlying abdominal skin located within the proximity of the umbilicus.

Results The result of this technique produced a definitive means of identifying and delivering the umbilical stalk during abdominoplasty. This technique has been performed in 23 consecutive abdominoplasty procedures with no difficulties locating the umbilical stalk and no infections resulting from the procedure.

Conclusions Accurate identification of the umbilicus provides the ability to create an aesthetically pleasing neo-umbilicus, thus optimizing abdominoplasty results.

Level of Evidence IV This journal requires that authors assign a level of evidence to each article. For a full description of these Evidence-Based Medicine ratings, please refer to the Table of Contents or the online Instructions to Authors www.springer.com/00266.

Keywords Abdominoplasty · Neo-umbilicus · Spherical stainless steel device · Umblicator · Umbilicoplasty · Umbilicus

A. Mowlavi (✉)
Cosmetic Plastic Surgery Institute, 31542 Pacific Coast
Highway, South Laguna Beach, CA 92677, USA
e-mail: amowlavi@gmail.com

P. M. Huynh
University of Cincinnati College of Medicine, Cincinnati,
OH 45267, USA

D. C. Huynh
University of California, Irvine, Irvine, CA 92697, USA

B. J. Wilhelmi
Department of Surgery, University of Louisville, 550 South
Jackson, 2nd Floor ACB, Louisville, KY 40059, USA
e-mail: bjwilh01@louisville.edu

The umbilicus is the first and central focus during a glance at an aesthetically pleasing female abdomen. Its features include a natural-appearing depressed outline within a shadow, with an average skin island diameter of 1.0–1.5 cm located ideally along the midline [1, 2]. Because the appearance of the umbilicus is critical to obtaining outstanding results after abdominoplasty, surgeons have strived for the best replication of these features [3].

Multiple goals must be accomplished in creating an aesthetically pleasing umbilicus. These goals include choosing the appropriate position of the umbilicus, locating

the umbilicus position on the overlying abdominal skin, and shaping the umbilicus [4]. Although many descriptions for the proper positioning of the umbilicus during abdominoplasty exist, only a few techniques have been used to locate the umbilical stump on the overlying abdominal skin, and none are ideal.

Several prior techniques have attempted to ease location of the fixed umbilical stalk on the overlying redraped and repaired abdominal skin. One technique advocates fixation of the umbilical stalk at the intersection of a line spanning between the anterior superior iliac spines and the midline. The anterosuperior iliac spines are the highest point on the iliac crest [2, 5–7]. After umbilical stalk fixation to the abdominal fascia and redraping of the abdominal skin, this technique then assumes that the umbilicus will be found directly under the aforementioned approximated position. This technique is not ideal because it is difficult to replicate and only approximates the umbilical location.

Another technique involves visually locating the umbilicus during partial closure of the redraped abdominal skin flap. This visualization allows for marking of the umbilical stalk on the overlying abdominal skin flap while it is only partially repaired. This technique is not ideal because the skin may theoretically shift during completion of the closure, and the degree of shift would likely be dependent on the amount of skin left temporarily unrepaired during visualization of the umbilical stalk. A shift in the location of the marking also would be observed if the redraped skin was pulled tighter than initially anticipated [8]. Additionally, it often is difficult to identify the umbilical stalk position accurately because the surgeon is relying on his visualization and approximation of the umbilical stalk position with palpation of his or her finger.

Although the aforementioned techniques serve to approximate the location of the umbilicus generally, a small deviation of a few millimeters is sufficient to compromise the appearance of the umbilicus.

Several less popular umbilical positioning and locating parameters have been described. One technique advocates locating the umbilicus by using distance ratios of different landmarks to the umbilicus such as the ratio of the xiphoid to the umbilicus and the anterior superior iliac crest to the umbilicus. It has been noted that the distance ratio between the xiphoid to the pubic symphysis and the xiphoid to the umbilicus should be approximately 1.6:1 [8]. Another anatomic description locates the umbilicus at the level of the anterior fibrocartilage corresponding to the third and fourth lumbar vertebrae [8–10]. The difficulty with these approaches revolves around the fact that every individual is unique, and generalized landmarks do not always exactly match the individual patient.

This report introduces a unique technique to remedy the difficulty of identifying the location of the umbilicus after

redraping of the abdominal skin flap. A stainless steel marble measuring 1.5 cm in diameter with three 2-mm-diameter holes drilled 120° apart in an equilateral triangle (Figs. 1 and 2), is fastened to the umbilicus and allows the surgeon to identify the location of the umbilicus definitively using simple palpation of the overlying redraped and repaired abdominal skin. The 2-mm hole size allows the marble to be held and controlled with Adson pickups.




Fig. 1 The stainless steel marble with a suture threaded through one of the drill holes

Equatorial plane of the stainless steel marble

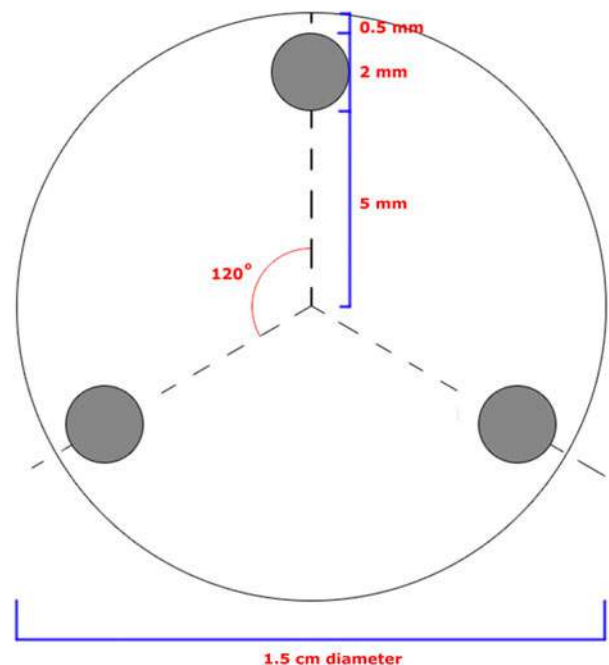


Fig. 2 A schematic of the device. Three 2-mm-diameter holes are drilled perpendicular to the equatorial plane of the marble. Each hole is spaced exactly 120° apart and 0.5 mm from the edge of the plane

Methods and Materials

Abdominoplasty with full-muscle plication and neo-umbilical reconstruction was performed to test the effectiveness of the new technique. After elevation of the abdominal skin, completion of abdominal muscle plication, and fixation of the umbilicus, the stainless steel marble, called the Umblicator, is secured to the umbilicus (Figs. 3 and 4). The Umblicator, a stainless steel ball with three drilled holes (Figs. 1 and 2), is secured to the top of the umbilical stalk with a 3-0 suture on a P-3 or PS2 needle. The Umblicator is secured to the inferior and superior dermis of the umbilical stalk using any two holes located 120° apart. Finally, the third loop is threaded through the remaining top holes to create a suture loop handle roughly 2 cm in diameter to assist in delivering the marble.

Once the marble is secured, the superior abdominal flap is redraped and trimmed, and the suture is repaired, the

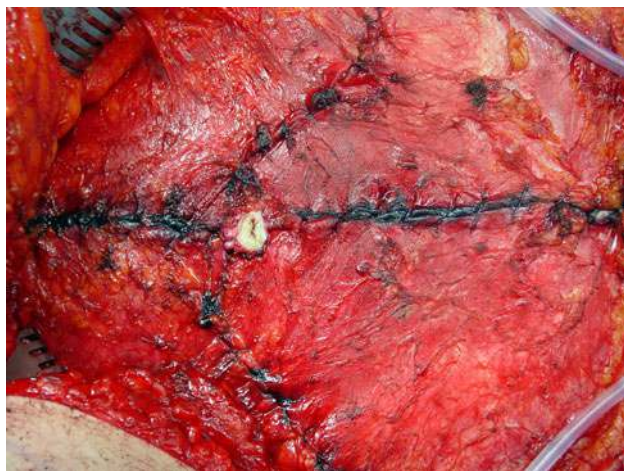


Fig. 3 The umbilical stalk after fixation to the abdominal fascia

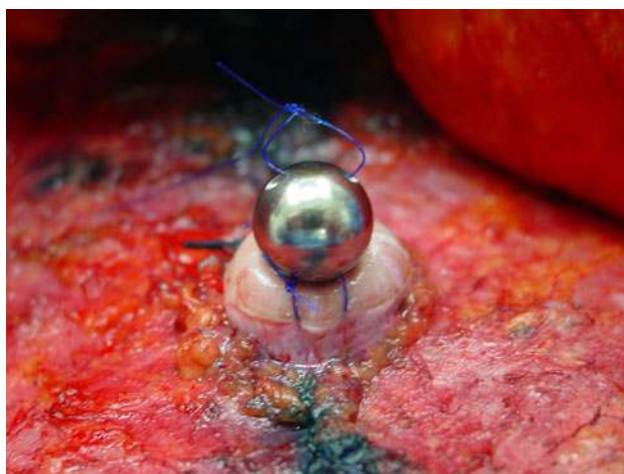

Fig. 4 Fixation of the Umblicator on top of the umbilical stalk

location of the umbilicus is determined by feeling for the smooth spherical surface bump with gentle downward pressure on the overlying abdominal skin located within the proximity of the umbilicus. Once the umbilicus is located, a vertical oval excision is made to deliver the marble and inset the neo-umbilicus. The loop-forming suture handle attached to the marble is used to exteriorize the marble. The umbilical stalk is sutured onto the surrounding skin to complete the neo-umbilicus (Fig. 5).

Results

The result of this technique produced a definitive means of identifying and delivering the umbilical stalk during abdominoplasty. Creating an oval excision of the abdominal skin directly overlying the Umblicator, and thus the umbilical stalk, ensures optimized shaping of the umbilicus without unnecessary tension or distortion of the neo-umbilicus.

Discussion

An aesthetically positioned and shaped umbilicus is critical to achieving optimum results during abdominoplasty. Neo-umbilicus creation has been an obstacle for surgeons. The use of the Umblicator allows the surgeon to locate the umbilicus effectively and thus to deliver and shape it.

In addition to using the Umblicator, the primary surgeon also used an additional technique to ensure appropriate identification of the umbilical stalk location. Before redraping and repair of the abdominal skin flap, the distance between the pubic symphysis, a midline bony anatomic landmark, and the umbilical stalk is measured.

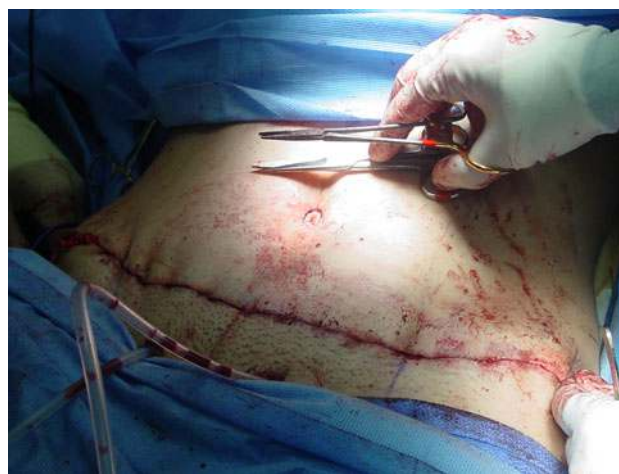

Fig. 5 Creation of the neo-umbilicus

This distance then is transposed onto the redraped and repaired abdominal skin. This additional technique guards against potential complications that may arise with use of the Umblicator. First, it is conceivable that the overlying upper epigastrium subcutaneous tissue could be generous enough in thickness to make palpation of the marble difficult. Additionally, in theory, it is conceivable that the fixation sutures may break, thus dislodging the marble from the top of the umbilical stalk. To avoid this complication, it is recommended that a 3-0 grade suture be used for fixation. As such, both the aforementioned localization technique using the bony anatomic landmark of the symphysis pubis and palpation of the underlying Umblicator ensure ease of umbilical stalk identification and delivery to optimize umbilical appearance (Fig. 5).

An ideal abdominoplasty outcome may be compromised by improper positioning and thus the appearance of the neo-umbilicus [5]. The difficulty of the partial closure visualization technique for locating the neo-umbilicus is that slight movements of the redraped and repaired abdominal skin after initial markings can result in miscalculation of the proposed neo-umbilicus position. This shift in umbilical location after initial marking can occur either from a shift of the overlying abdominal skin flap during completion of the abdominal skin repair or from inadvertent changes in the operating room table flexion settings by the anesthesiologist. Even changes in the patient's breathing pattern can result in a patient's abdomen shifting a few millimeters.

With the Umblicator, the location of the umbilical stalk can be definitively identified on the redraped and repaired overlying abdominal skin. Currently, we have performed 23 consecutive abdominoplasty procedures with no difficulty locating the umbilical stalk and no infections resulting from the procedure.

Conclusion

Using the Umblicator allows the surgeon to identify the future site for the neo-umbilicus accurately and efficiently. Accurate identification of the umbilicus provides the ability to create an aesthetically pleasing neo-umbilicus and thus to optimize abdominoplasty results.

Acknowledgments The funding for the research and the creation of this report was provided solely by us without funding from any outside organization or entity. No outside organizations or entities assisted us in any form with the creation of this report.

References

1. Craig SB, Faller MS, Puckett CL (2008) In search of the ideal female umbilicus. *Plast Reconstr Surg* 121:356e–357e
2. Dubou R, Ousterhout DK (1978) Placement of the umbilicus in an abdominoplasty. *Plast Reconstr Surg* 61:291–293
3. Delerm A (1982) Refinements in abdominoplasty with emphasis on reimplantation of the umbilicus. *Plast Reconstr Surg* 70: 632–637
4. Shoukas J, Christopoulos N, Kouris G, Polley J (2009) Umbilical quest: a new technique for accurately identifying the new position of the umbilicus in abdominoplasty using a lockwood marker. *Plast Reconstr Surg J* 123:120e–121e
5. Al-shaham A (2009) Neoumbilicoplasty is a useful adjuvant procedure in abdominoplasty. *Can J Plast Surg* 17:e20–e23
6. Choudhary S, Taams KO (1998) Umbilicoculpture: a concept revisited. *Br J Plast Surg* 51:538–541
7. Bartsich SA, Schwartz MH (2003) Purse-string method for immediate umbilical reconstruction. *Plast Reconstr Surg J* 112:1652–1655
8. Abhyankar SV, Rajguru AG, Patil PA (2006) Anatomical localization of the umbilicus: an Indian study. *Plast Reconstr Surg* 117:1153
9. Grant B (1965) Grant's method of anatomy. Williams & Wilkins, Baltimore, MD
10. Dick ET (1970) Umbilicoplasty as a treatment for persistent umbilical infection. *Aust N Z J Surg* 39:380