

# Facial Fracture Approaches With Landmark Ratios to Predict the Location of the Infraorbital and Supraorbital Nerves: An Anatomic Study

Bradon J. Wilhelmi, MD,\* Arian Mowlavi, MD,\* Michael W. Neumeister, MD,\* Steven J. Blackwell, MD<sup>†</sup>

Springfield, Illinois

In exposing facial fractures for reduction and fixation with coronal, subciliary, subtarsal, and upper buccal sulcus approaches, the supraorbital and infraorbital nerves are susceptible to injury. The location of the supraorbital and infraorbital nerves can be predicted by palpating for the supraorbital notch. Significant edema as seen with facial fractures can make these prominent bony landmarks difficult to palpate, however. The purpose of this study was to determine a method to predict the location of the supraorbital and infraorbital nerves in the face of frontal and periorbital edema when the supraorbital and infraorbital nerves are not palpable. The supraorbital and infraorbital nerves were identified in 14 cadaver heads. The orbital width from the medial to lateral canthus was measured. The distance of the vertical vector of the supraorbital and infraorbital nerves from the medial canthus was measured along this horizontal vector of the orbit. The distance of the infraorbital nerve from the infraorbital rim was measured. The orbital width measured  $42.2 \pm 1.6$  mm from the medial to lateral canthus. The vertical vector of the supraorbital nerve measured  $15.9 \pm 1.1$  mm from the medial canthus along the horizontal vector of the orbit. The vertical vector of the infraorbital nerve mea-

sured  $16.8 \pm 1.4$  mm from the medial canthus along the horizontal vector of the orbit. The infraorbital nerve measured  $9.8 \pm 1.0$  mm inferior to the infraorbital rim. The medial one third of the orbit measured 14.1 mm. Therefore, the supraorbital and infraorbital nerves are located approximately along the medial third of the orbit, with the upper bound of 95% confidence at 3.1 mm. The location of the supraorbital and infraorbital nerves can be predicted by the previous landmark ratio to within 3 mm.

---

*Key Words:* Facial fractures, anatomic landmarks, infraorbital, superorbital nerves

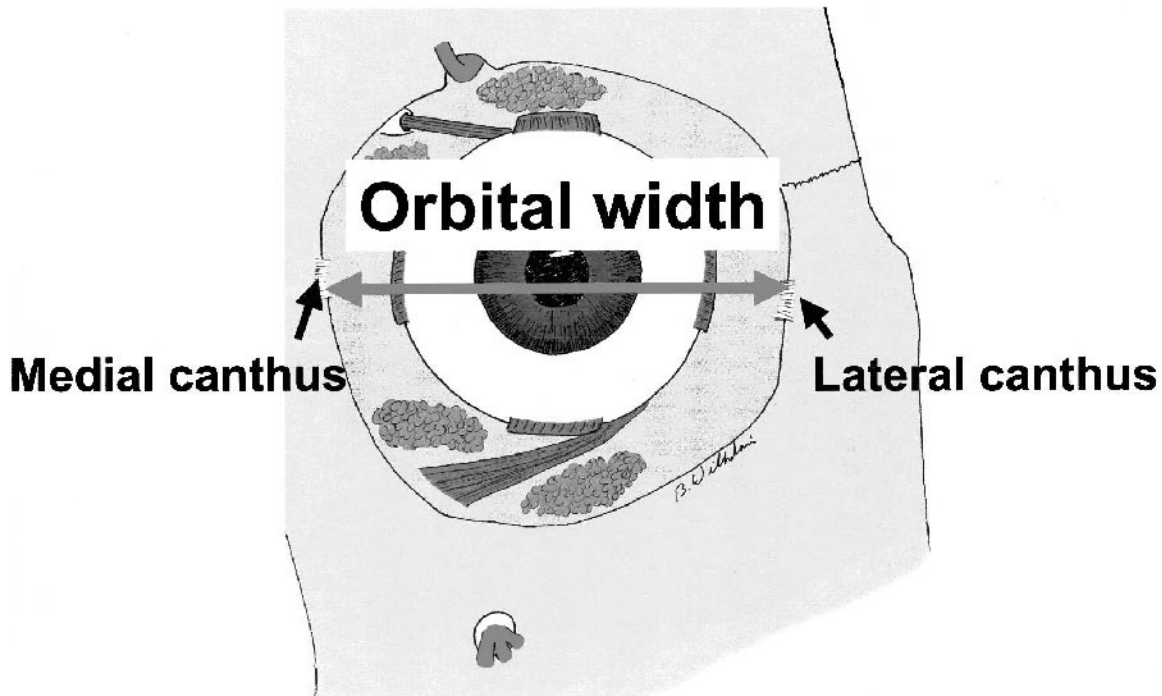
**I**n exposing facial fractures for reduction and fixation with coronal, subciliary, subtarsal, and upper buccal sulcus approaches, the supraorbital and infraorbital nerves are susceptible to injury. The location of the supraorbital and infraorbital nerves can be predicted by palpating for the supraorbital notch through which the supraorbital nerve emerges and the infraorbital canal from which the infraorbital nerves exits. Significant edema as seen with facial fractures can make these prominent bony landmarks difficult to palpate, however. Moreover, previously described predictors of the supraorbital and infraorbital nerves require the patient to have his or her eyes open and to be able to look straight ahead. At the time of surgery, patients usually have their eyes closed or directed in an unpredictable direction. The purpose of this study was to determine a method to predict the location of the supraorbital and infraorbital nerves in the face of frontal periorbital edema when the supraorbital and infraorbital foramen are not palpable.

---

From the \*Institute for Plastic Surgery, Southern Illinois University School of Medicine, Springfield Illinois; and <sup>†</sup>University of Texas Medical Branch, Galveston, Texas.

Address correspondence to Dr Wilhelmi, The Plastic Surgery Institute, Southern Illinois University School of Medicine, 747 North Rutledge, 3rd Floor, PO Box 19653, Springfield, IL 62794-9653; e-mail: bwilhelmi@siuimed.edu.

Presented at the Annual Scientific Meeting of the American Society of Plastic Surgeons, Orlando, Florida, November 3-7, 2001.



**Fig 1** The orbital width was measured for each cadaver from the medial orbital wall and the lateral orbital wall at the level of the medial and lateral canthal tendons.

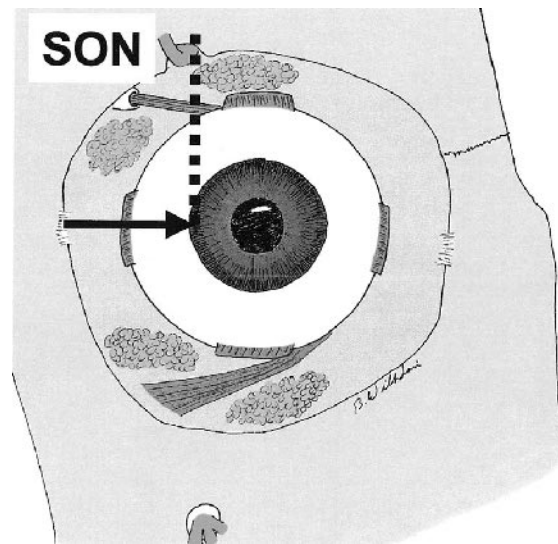
#### MATERIALS AND METHODS

The study design involved dissection of 14 cadaver heads in which the supraorbital notch and infraorbital canal were identified in relation to the medial and lateral orbital walls. The orbital width was measured for each cadaver from the medial orbital wall and the lateral orbital wall at the level of the medial and lateral canthal tendons (Fig 1). The distance of the vertical vector of the supraorbital notch and the infraorbital canal was measured along this horizontal vector from the medial orbit at the medial canthal tendon for each cadaver head (Fig 2). The distance of the infraorbital canal from the infraorbital rim was also measured for each cadaver (Fig 3).

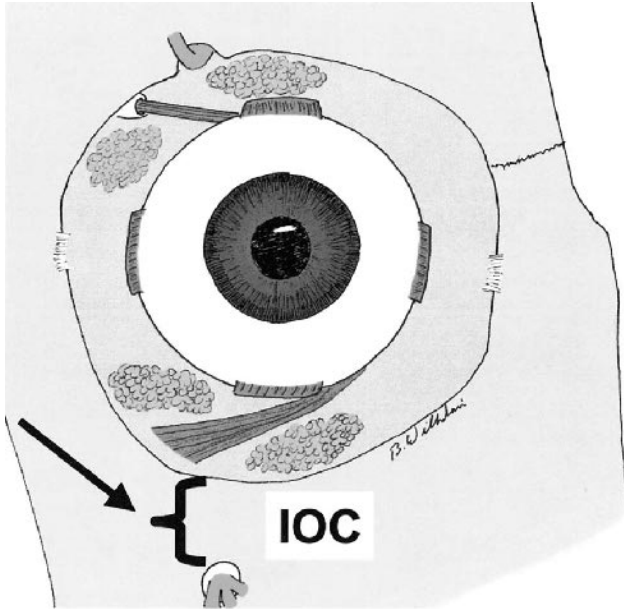
#### RESULTS

In these cadaver dissections, the orbital width measured an average  $42.2 \pm 1.6$  mm from the medial to lateral canthus. The average distance of one third of the orbit was 14.1 mm (Fig 4). The vertical vector of the supraorbital nerve measured  $15.9 \pm 1.1$  mm from the medial orbital wall at the medial canthus along the horizontal vector of the orbit (Fig 5). The vertical vector of the infraorbital canal measured  $16.8 \pm 1.4$  mm from the medial canthus along the horizontal

vector of the orbit (Fig 6). Also, the infraorbital nerve measured  $9.8 \pm 1.0$  mm inferior to the infraorbital rim (Fig 7). The medial one third of the orbit measured 14.1 mm. Again, the average distance of one third of

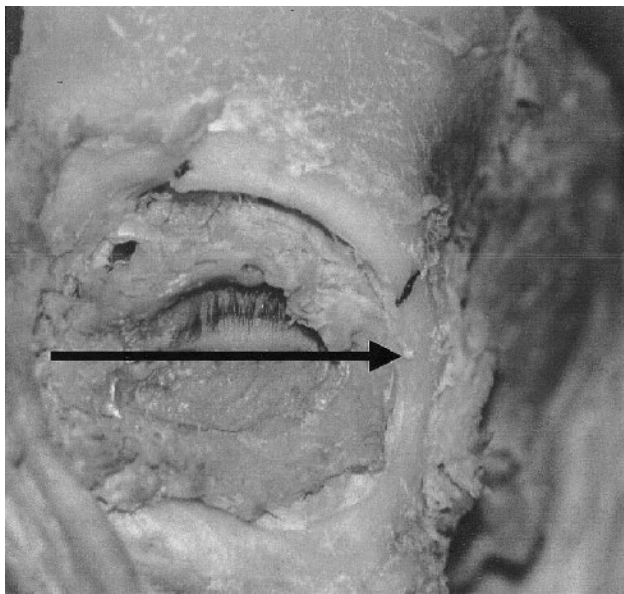


**Fig 2** The distance of the vertical vector of the supraorbital notch (SON) and the infraorbital canal was measured along this horizontal vector from the medial orbit at the medial canthal tendon for each cadaver head.

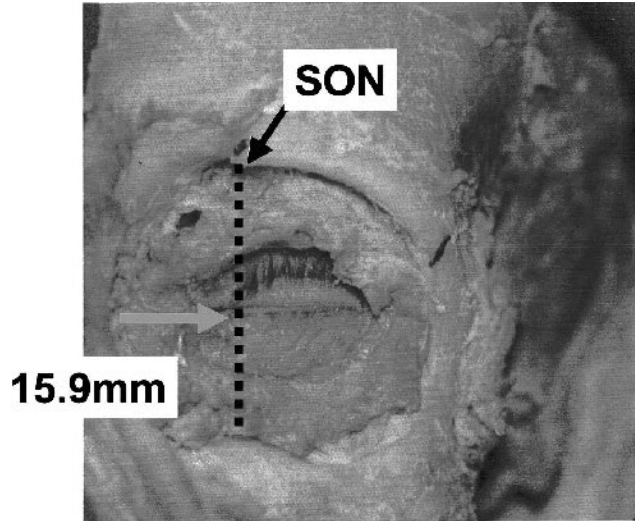


**Fig 3** The distance of the infraorbital canal (IOC) from the infraorbital rim was also measured for each cadaver.

the orbit was 42.2 mm. The distance from the medial wall to the supraorbital notch was 15.9 mm. The distance from the medial wall to the infraorbital rim was 16.8 mm. Therefore, the supraorbital and in-



**Fig 4** In these cadaver dissections, the orbital width measured an average  $42.2 \pm 1.6$  mm from the medial to lateral canthus. The average distance of one third of the orbit was 14.1 mm.

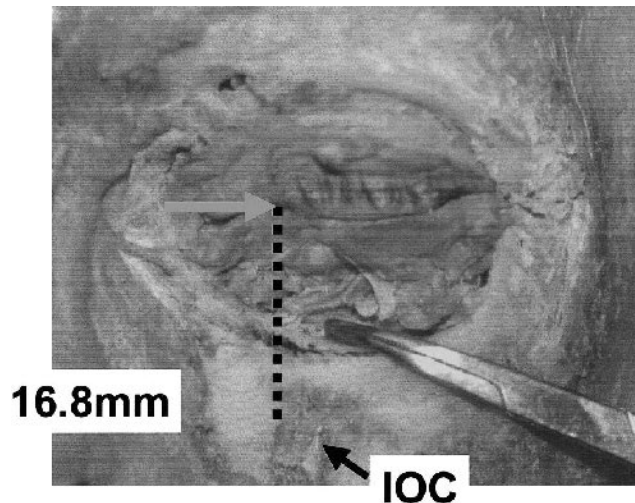


**Fig 5** The vertical vector of the supraorbital nerve (SON) measured  $15.9 \pm 1.1$  mm from the medial orbital wall at the medial canthus along the horizontal vector of the orbit.

fraorbital nerves are located approximately along the medial third of the orbit, with the upper bound of 95% confidence of 3.1 mm (Fig 8).

**DISCUSSION**

The supraorbital nerves are the terminal branches of the frontal nerve, which is the largest branch of the ophthalmic nerve. The supraorbital nerve provides sensation to the areas of the forehead and



**Fig 6** The vertical vector of the infraorbital canal (IOC) measured  $16.8 \pm 1.4$  mm from the medial canthus along the horizontal vector of the orbit.

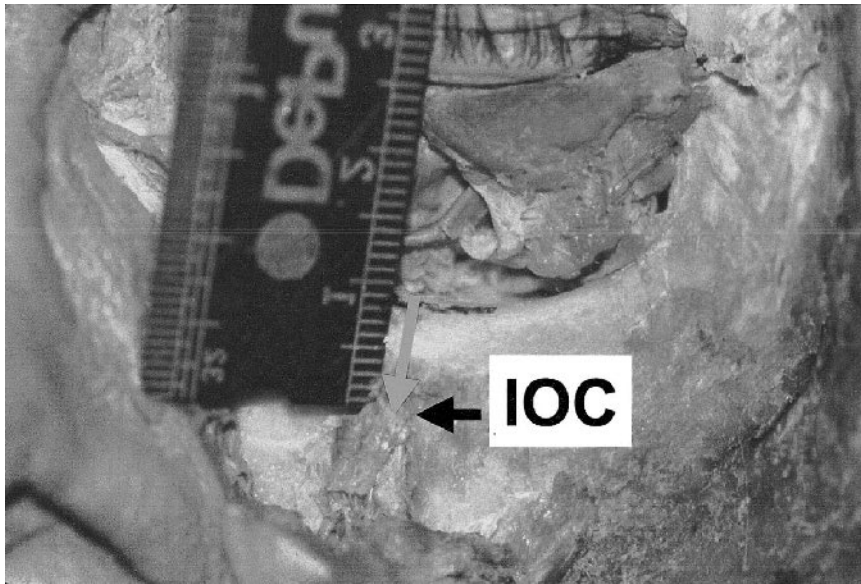


Fig 7 The infraorbital nerve measured an average of  $9.8 \pm 1.0$  mm inferior to the infraorbital rim. IOC, infraorbital canal.

scalp. In the lower forehead, the supraorbital nerve provides sensory feedback from the medial to lateral edge of the brows. The upper forehead and scalp are innervated by the supraorbital nerve. The supraorbital nerve emerges from the orbit through the supraorbital foramen or notch.

The infraorbital nerve is a component of the trigeminal nerve. The infraorbital nerve provides sensation to the cheek and upper lip. The boundaries of the sensory dermatome of the infraorbital nerve include the ciliary margin to the lip and the lateral canthus to the nasal midline. The borders of this dermatome have an overlapping nerve supply. The infraorbital nerve exits the infraorbital canal. The supraorbital and infraorbital nerves have been described to be found along a vertical line through the medial aspect of the pupil.<sup>1</sup>

Use of the pupil as a predictor of the supraorbital and infraorbital nerves requires the patient to have his or her eyes open and to look straight ahead. At the time of surgery, however, patients usually have their eyes closed. Our ratio of the medial third of the orbit can be used to predict the location of the supraorbital notch in this circumstance.

Studies of the infraorbital canal distance from the infraorbital edge have been performed. In a study of 15 Egyptian cadavers, the infraorbital canal was found to be  $6.1 \pm 2.4$  mm to the inferior orbital margin.<sup>2</sup> In a study of 16 cadavers in Greece, the infraorbital foramen was located 7.19 mm below the infraorbital rim.<sup>3</sup> We found the infraorbital canal located an average of  $9.8 \pm 1.0$  mm below the infraorbital rim. The variations in these measurements can be explained by anthropometric differences expected in different races and nationalities.

plained by anthropometric differences expected in different races and nationalities.

With descriptive analysis, we found the supraorbital notch and infraorbital canal within 3.1 mm of the medial third of the orbit 95% of the time. Thus, this ratio of dividing the orbit into thirds can be used

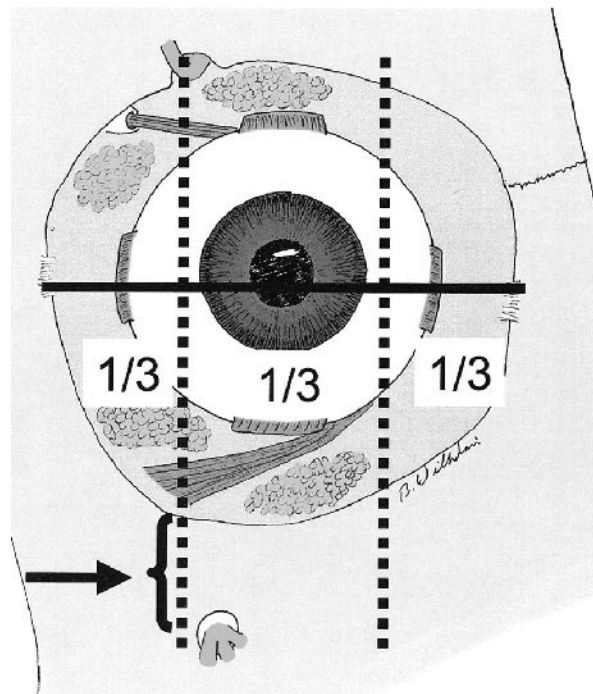


Fig 8 The supraorbital and infraorbital nerves are located approximately along the medial third of the orbit.

to predict the location of the supraorbital notch and infraorbital canal to within 3.1 mm. Obviously, if the patient has significantly displaced nasoethmoidal or zygomaticomaxillary fractures, these ratios may not be accurate. These measurements and ratios can also be used when reconstructing the fronto-orbital area after significant panfacial fractures.

#### CONCLUSION

The location of the supraorbital and infraorbital nerves can be predicted to be along the vertical vector of the medial third of the orbit with 95% confidence, and the infraorbital canal can be predicted to be 1 cm below the infraorbital rim (see Fig 8). Perhaps these guidelines can be used to minimize the

risk of injury to the supraorbital and infraorbital nerves or when reconstructing severe panfacial fractures.

---

The authors thank Janet Ketchem, CST, for providing assistance in organizing our dissections.

---

#### REFERENCES

1. Moore DC. *Regional Block*. 4th ed. Springfield: Charles C. Thomas, 1965:72-77
2. Hindy AM, Abdel-Raouf F. A study of infraorbital foramen, canal and nerve in adult Egyptians. *Egypt Dent J* 1993;39:573-580
3. Triandafilidi E, Anagnostopoulou S, Soumida M. The infraorbital foramen (the position of the infraorbital foramen in man) [in Greek]. *Odontostomatol Proodos* 1990;44:87